

- Helicobacter -

THE EASE AND DIFFICULTY
OF A NEW DISCOVERY

Robin Warren

EARLY DAYS

- First reports 100 years ago
 - considered spirochaetes
- 1940 Freedburg saw curved organisms in the stomach
- 1954 Palmer: “Freedburg was wrong”

MEDICAL TEACHING ADAMANT

- Acid environment kills organisms
- The normal stomach is **sterile**
- Bacteria seen are
 - contaminant passing through
 - dead, or –
 - secondary to gastric lesions such as peptic ulcer
 - **usually fungus or yeast in necrotic debris**
- Primary infection is rare

GASTRIC BIOPSIES ----- pre 1970

- Good quality biopsies were rare
- Specimens were usually **Surgical** or **Post mortem**
- Mucosa soon autolysed in digestive juice
- Helicobacter rapidly disappear

GASTRITIS ----- pre 1970

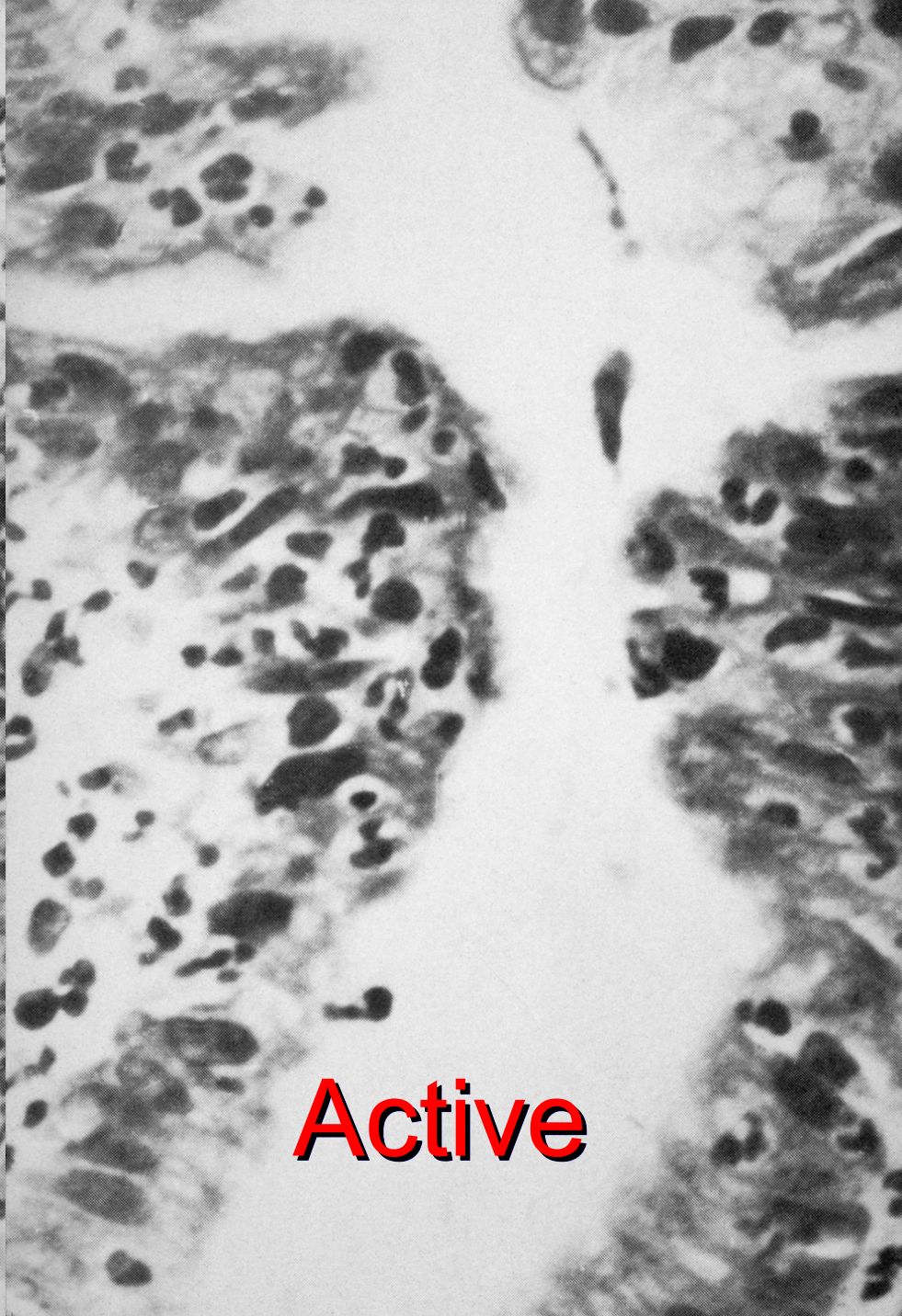
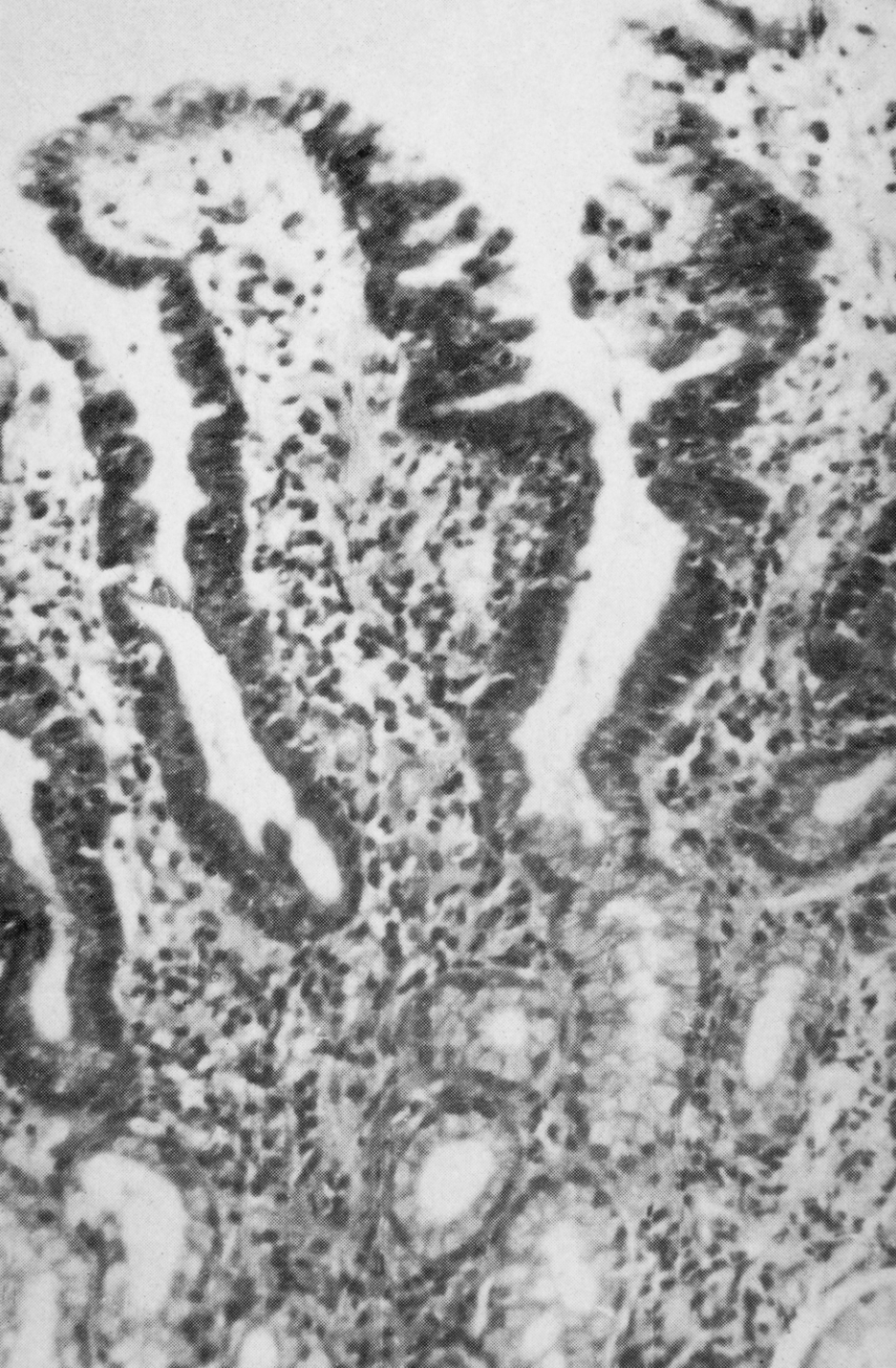
- clinical specimens were technically inadequate
- **acute** gastritis or **aplasia** with pernicious anaemia easily diagnosed but rare
- **chronic** inflammation was difficult to:-
 - **relate to the clinical findings**
 - **see, describe or classify**

MAJOR BREAKTHROUGHS IN THE 1970'S

- Numerous, small well-fixed biopsies
- Histology of gastric mucosa finally seen clearly by pathologists

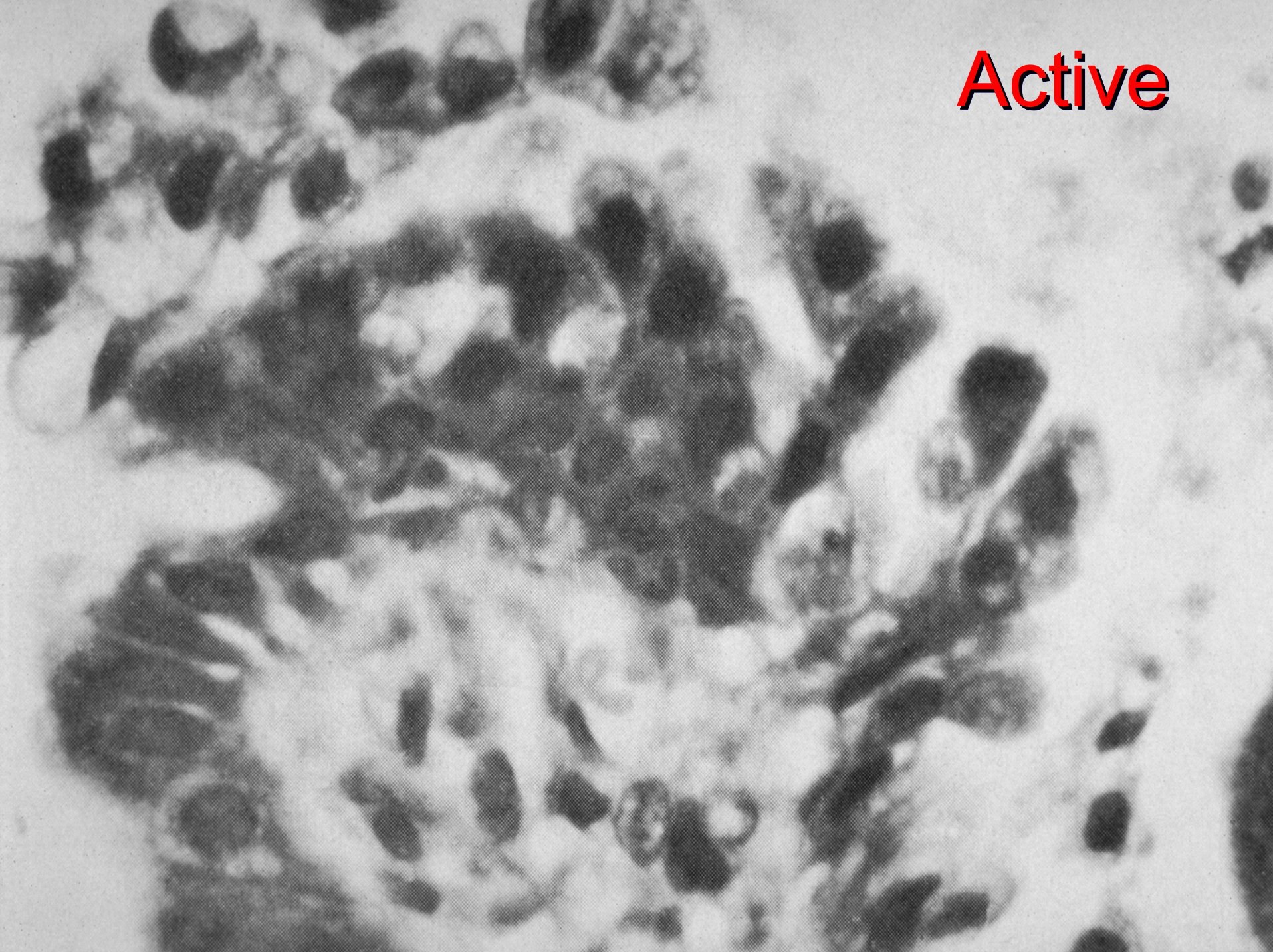
RICHARD WHITEHEAD - 1972

- accurately described them
- He defined **“active” gastritis**:-
 - specific epithelial changes and leucocyte infiltration



Active

Active



WHITEHEAD'S CLASSIFICATION

- He designed a new **classification**
- Logical, practical, descriptive
- Set out as a tree, apparently complex
 - But easy to use

WHITEHEAD 1972

<i>Mucosal Type</i>	<i>Grade of Gastritis</i>	<i>Metaplasia</i>
Pyloric Body	Superficial { Quiescent Active	Pseudo-pyloric
Cardiac	Atrophic { Mild Moderate Severe	{ Quiescent Intestinal Active
Transitional Indeterminate		

SIMPLIFICATION OF WHITEHEAD'S CLASSIFICATION

AS USED BY ME:-

- **Severity** - mild, moderate, severe
- **“Active”** or not
- **Type** of inflammation - acute or chronic
- **Other features** - atrophy, metaplasia

BACTERIAL STAINS

- I was interested in stains
- **Microbiology** stains clean smears
- More difficult with **histology**
- Tissues stain with bacterial stain
- Exceptions: Gram and Ziehl-Neelsen
- **Silver** used for spirochaetes and Donovan bodies in tissues
- I experimented with them successfully

BACKGROUND TO DISCOVERY

- A decade of well-fixed gastric biopsies
- Whitehead's description & classification
 - Active gastritis
 - My interest
- Bacterial stains
- My other interests
 - Fine detail and drawing
 - Photography
 - Electron microscopy

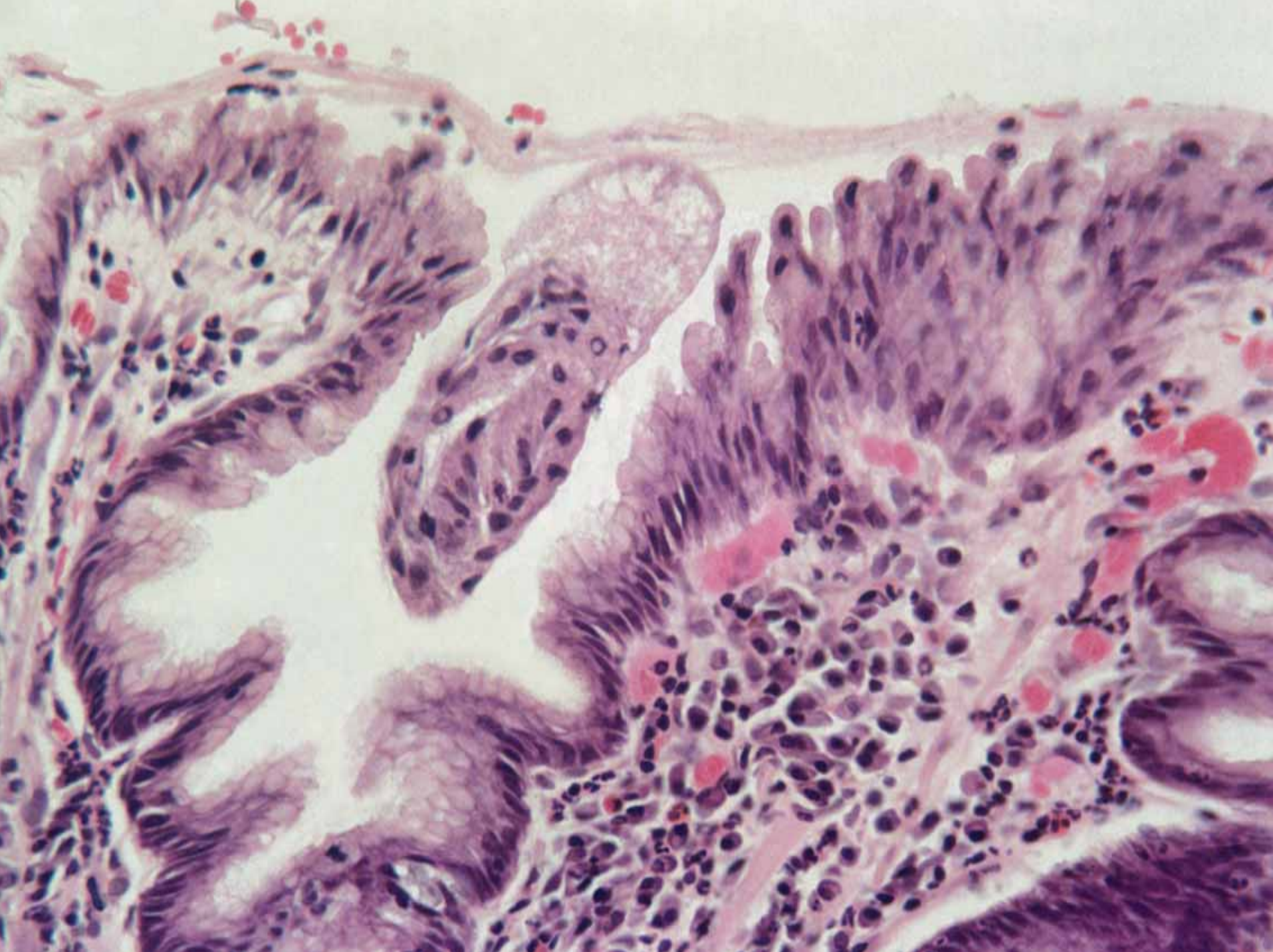
HELICOBACTER AND ME – JUNE 1979

ROUTINE GASTRIC BIOPSY

- Severe active chronic gastritis
- Unusual blue line on the surface

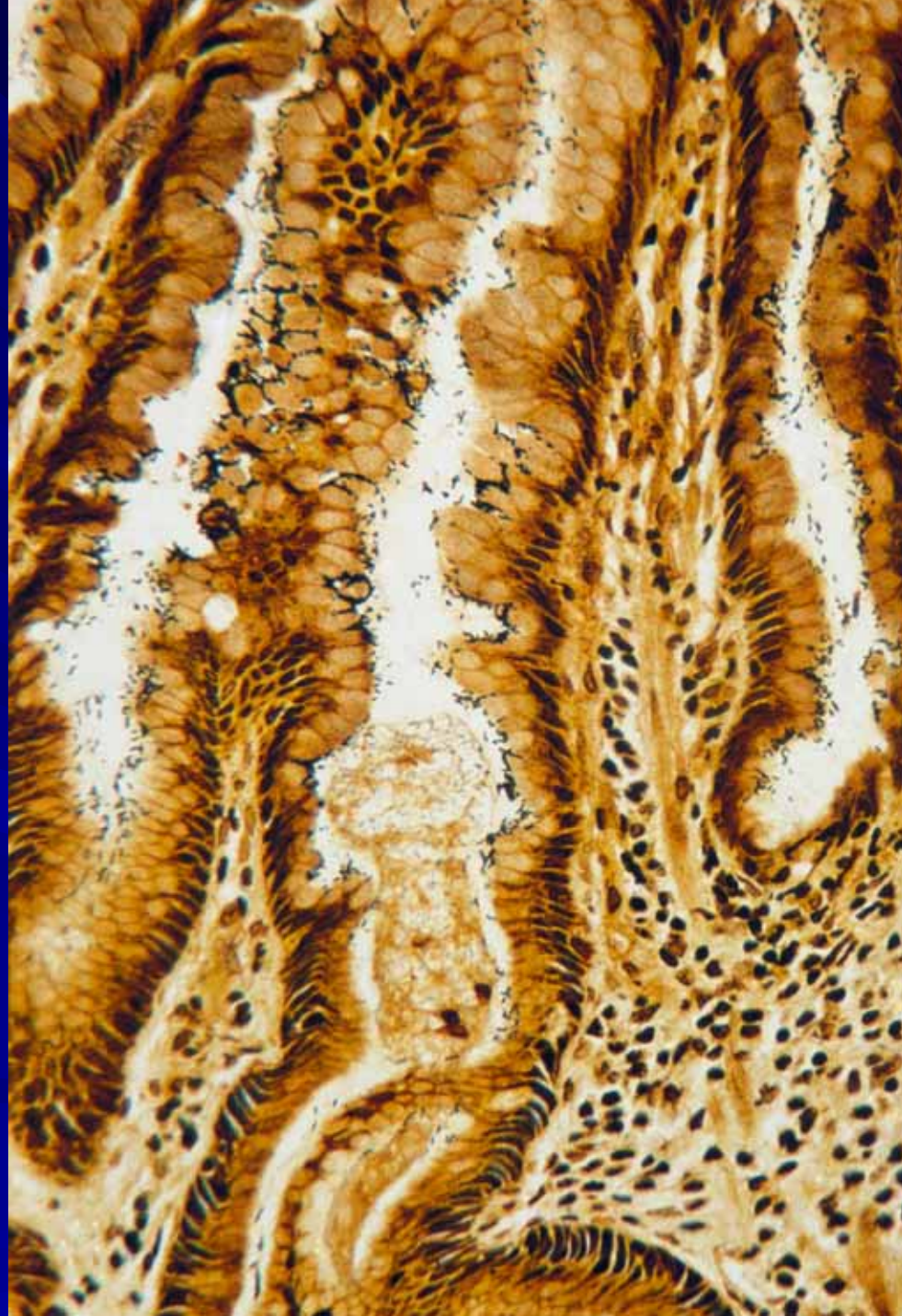
HIGH MAGNIFICATION

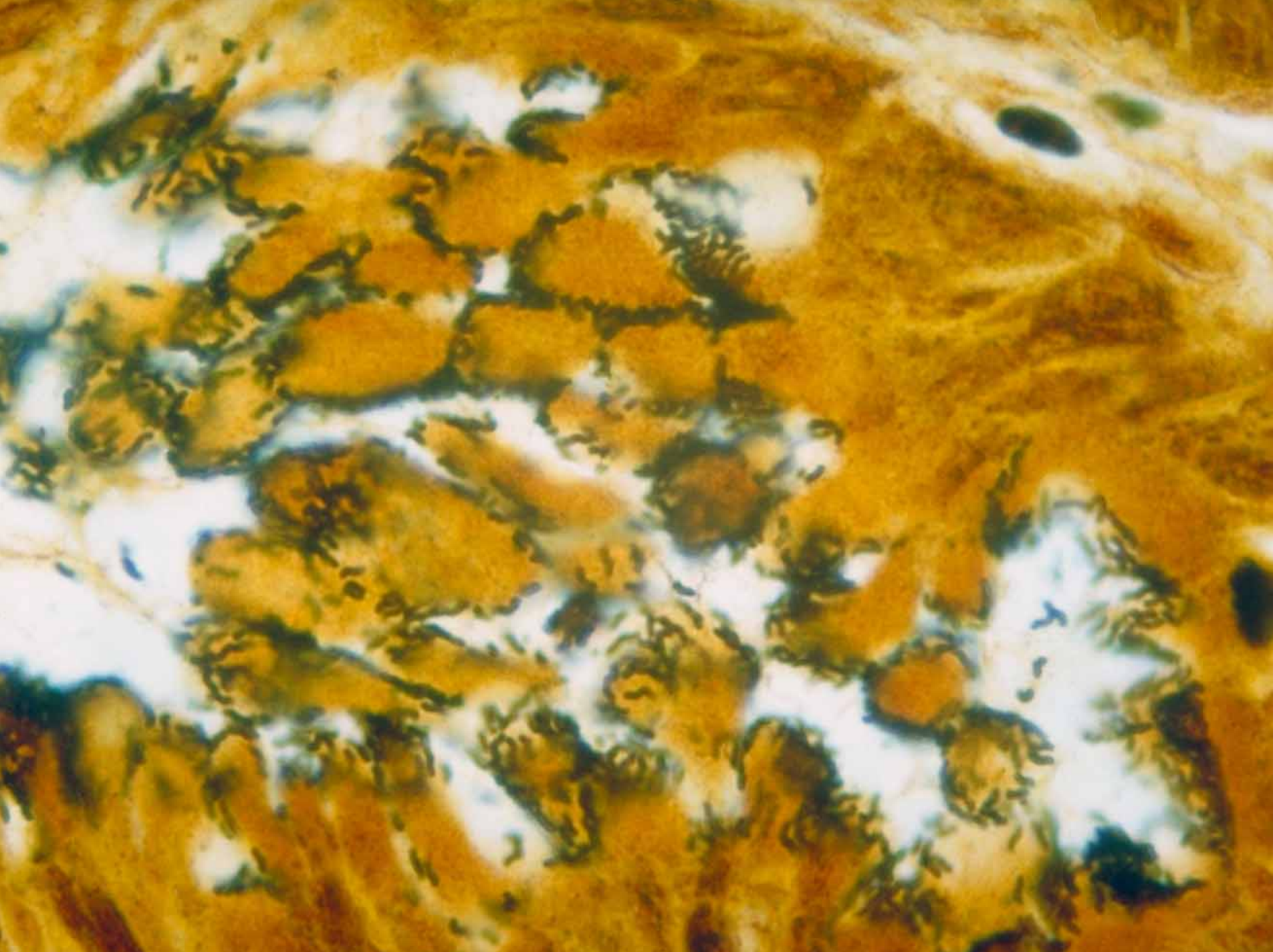
- numerous small curved bacilli
- Warthin-Starry stain showed bacteria clearly




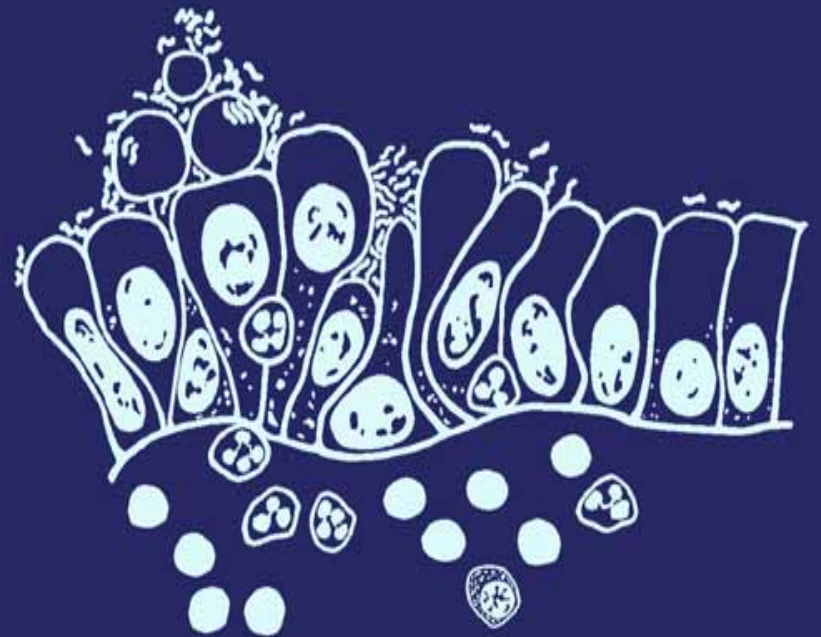
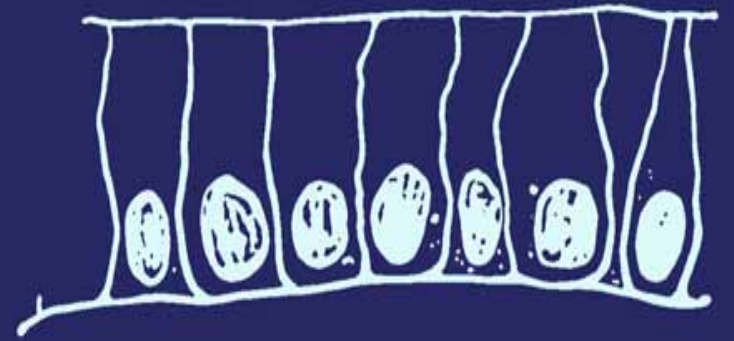
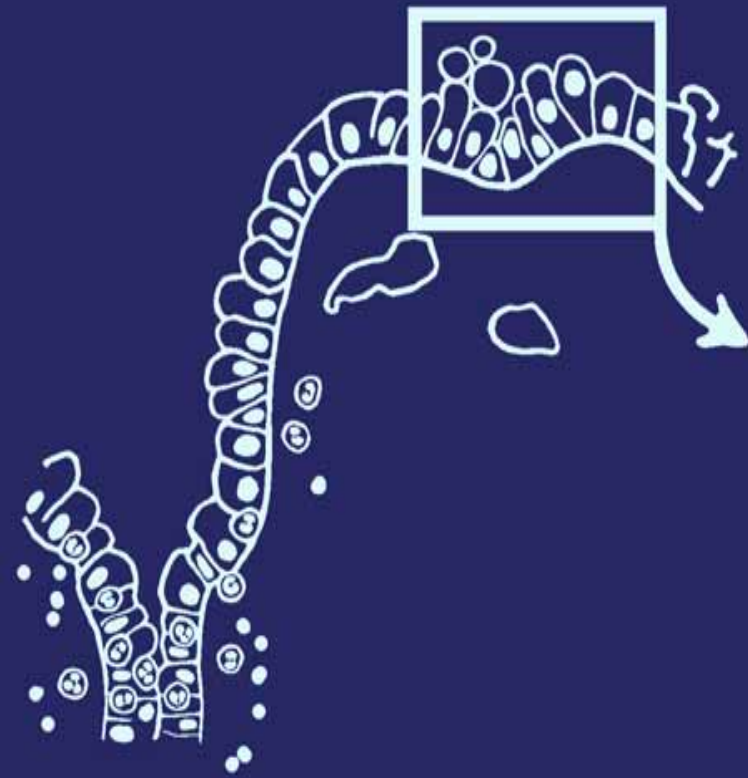
SILVER STAIN

- Black bacilli line the pits.
- Easily seen.







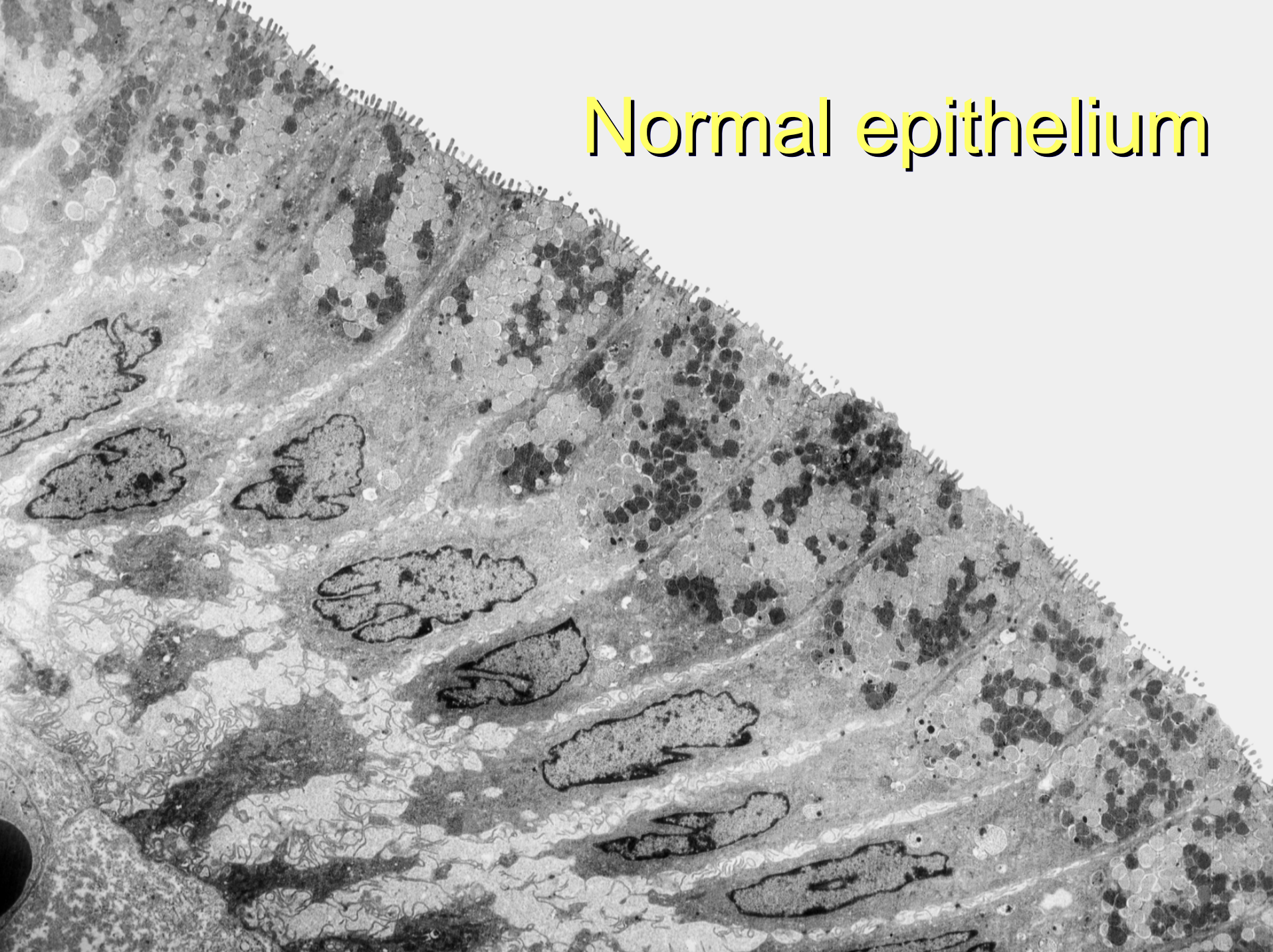


ELECTRON MICROSCOPY

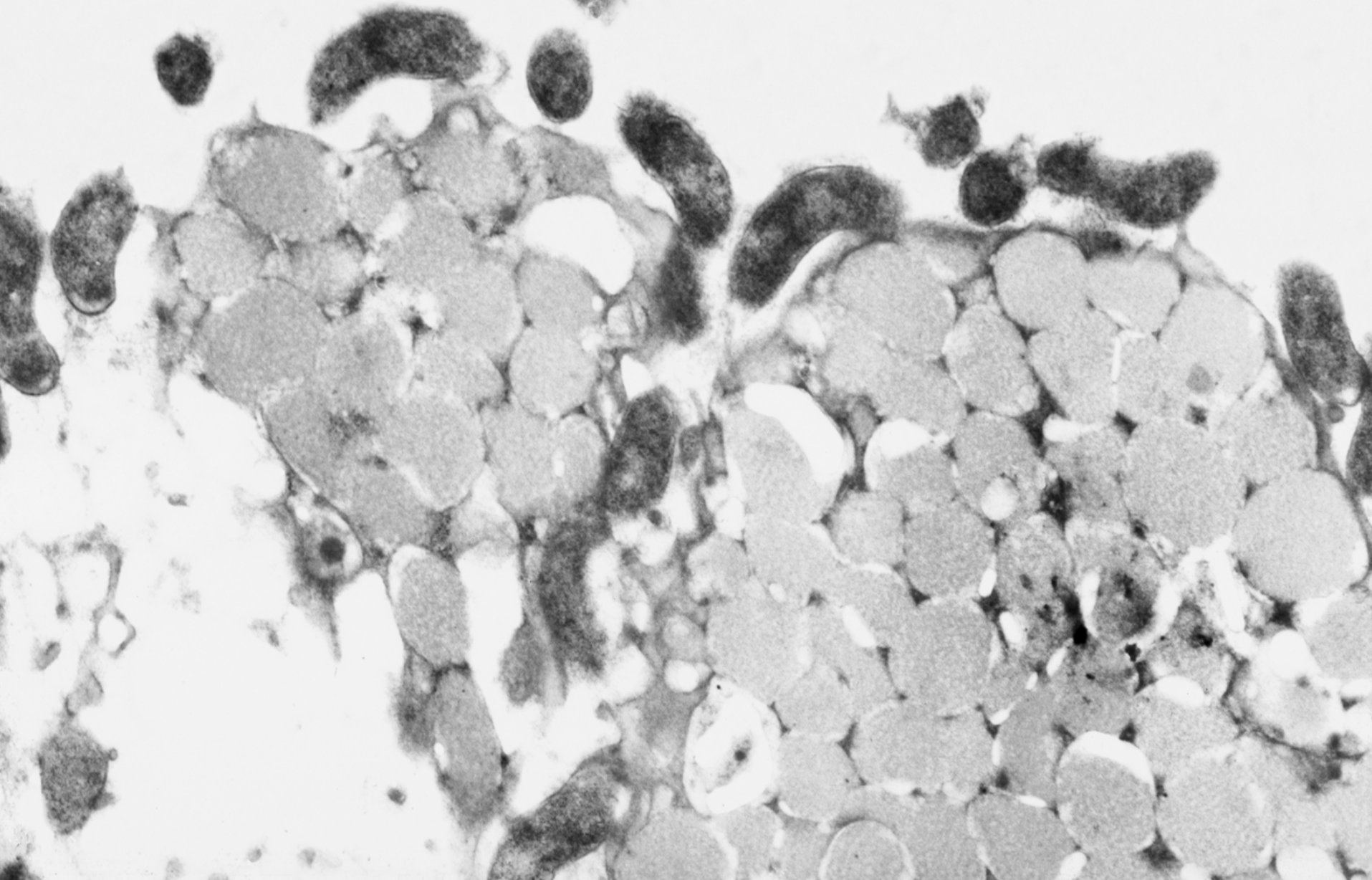
- Electron microscopy was of good quality
- Showed bacteria resembling Campylobacter
- Closely adherent to the cell surface

- My colleagues were finally convinced, but not impressed

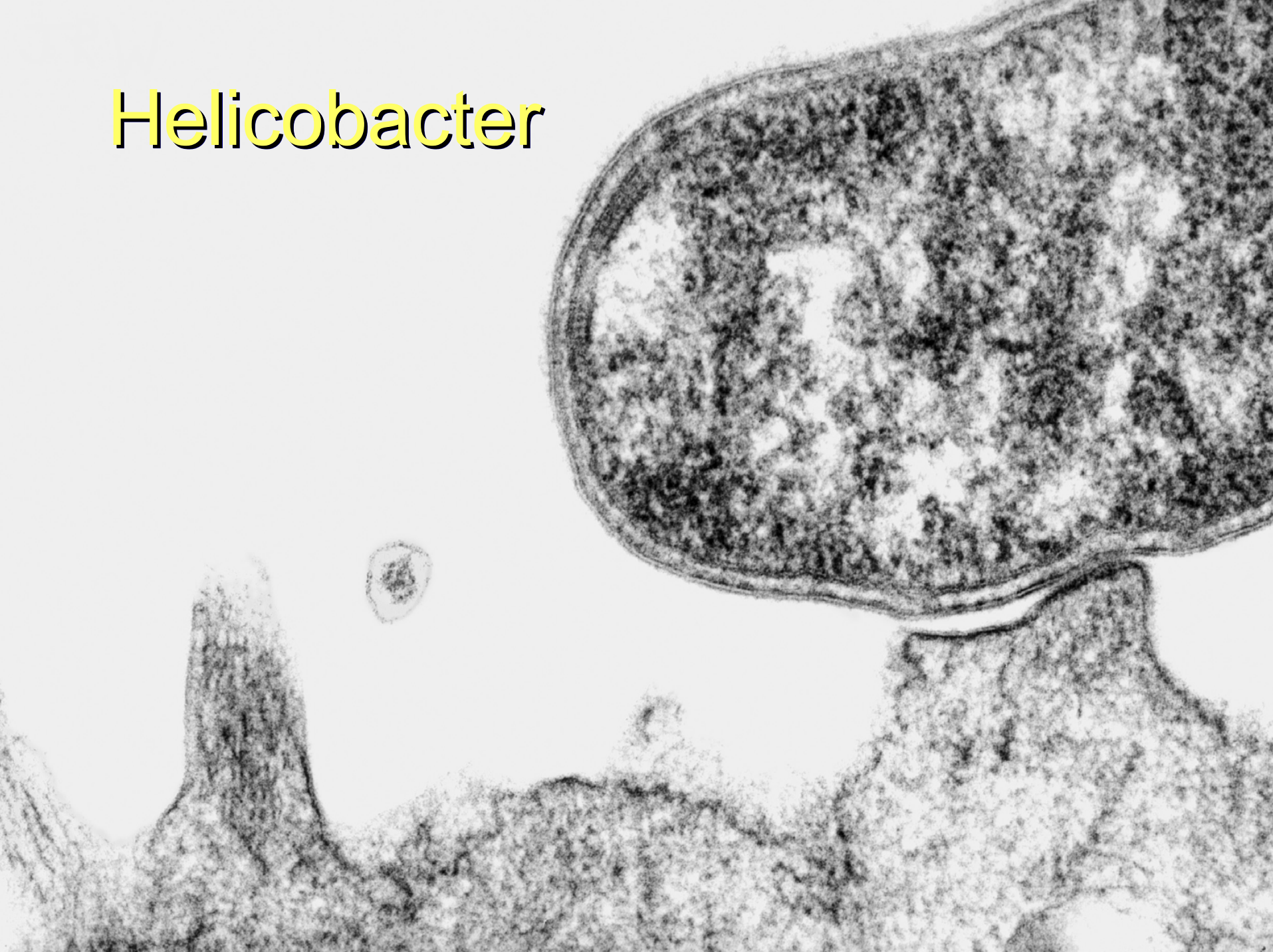Normal epithelium



Electron microscopy



Helicobacter



MY FIRST REPORT

Conclusion:

There is chronic gastritis with a small erosion. The quality of the surface mucus appears slightly more dense than normal in many areas, and it contains numerous bacteria in close contact with the surface epithelium. These bacteria have the morphology of Campylobacter. They appear to be actively growing and not a contaminant. I am not sure of the significance of these unusual findings, but further investigation of the patient's eating habits, gastro-intestinal function and microbiology may be worthwhile.

FOLLOWUP

- I examined all gastric biopsies for the bacteria
 - Not expecting to find more
- Found them in almost half the biopsies
 - Usually associated with histological **gastritis**
 - Often **severe** and often “**active**”
- Reporting of the organisms became routine
 - No-one else believed they were of significance

DIFFICULTIES

DISBELIEF

- Just a secondary infection, due to the gastritis
- “If it is true, why were they not recognised before?”

LABORATORY MEDICINE

- **No patient contact**
- Poor biopsies for my purposes
- Taken from obvious lesions, ulcer or neoplasm
- Taken from any part of the stomach

BARRY MARSHALL 1981

- My findings were ready for publication (summary, Lancet 1983)
- Barry, gastroenterology registrar, needed a project for publication
- Sent to “that pathologist who is trying to make gastritis an infection”

BARRY MARSHALL 1981

- He agreed to a short series of gastric biopsies
- Taking apparently normal antral mucosa, away from any local lesions
- He was enthusiastic
- Finally I had a **clinician** as a collaborator

MAJOR STUDY 1982

100 sequential outpatients for gastroscopy

- Formal, blind
- Detailed clinical protocol
- Biopsies for pathology and culture
- Tissue from “normal” antral mucosa
- Culture using *Campylobacter* techniques

UNEXPECTED RESULTS

HISTOLOGY UNRELATED TO:-

- Symptoms except
 - Bad breath
 - Burping
- Gastroscopic findings except
 - **DUODENAL ULCER**

SUCCESS

BACTERIA CULTURED

- New species

DUODENAL ULCER

- Strongly related to the infection
- We were surprised

PUBLICATIONS and PAPERS

1983 LANCET

- My summary
- Barry's summary of our combined work

1983 BRUSSELS

- Campylobacter conference
- Barry presented our results
- Skirrow enthusiastic

PUBLICATIONS and PAPERS

1984 LANCET

- Our definitive paper presented
- Delayed by disbelieving reviewers
- Skirrow repeated our work, wrote to Lancet
- Our paper published unaltered

LATER WORK

Diagnosis

- CLOtest, serology and breath test invented or suggested by Dr Marshall

Treatment

- Barry saw Bismuth mentioned in Osler's Textbook of Medicine
- Wondered if Denol worked by killing the bacteria
- He invented triple therapy in 1984

Proof

- Barry and Dr Arthur Morris used Koch's postulates
- Treating duodenal ulcers with triple therapy

EXAMPLES

- **Initial acute gastritis**, rapidly responding to treatment
- Barry infecting himself, to fulfil Koch's postulates

- **Chronic gastritis**, not responding to multiple courses of therapy
- Dr Arthur Morris, gave himself chronic gastritis to use Koch's postulates

- **Duodenal ulcer due to NSAIDs**
- My wife, who also had *H pylori*. After treatment for it, she could take NSAIDs

- **Most people with *H pylori* are symptomless**
- Myself. When my wife was treated, she found I had bad breath

DU STUDY, 1986

- All treated for ulcer
- Uncertain numbers treated for *H pylori*
 - Blind study
- Repeated biopsies
 - 12 months and 7 year follow-up
- Excellent for study of *H pylori* pathology

QUANTIFICATION OF GASTRITIS

■ Specific features

- Cobblestone change
- Polymorph infiltration

■ Non-specific changes

- Mucus secretion
- Lymphoid infiltration

■ Each given a value 0 – 9, total of 36

QUANTIFICATION OF GASTRITIS

- Before and after treatment
- Biopsy 2 weeks after treatment
- Histogram
 - Patient numbers against pathology
 - Total change after treatment

HELICOBACTER AND GASTRITIS

Patients

30

25

20

15

10

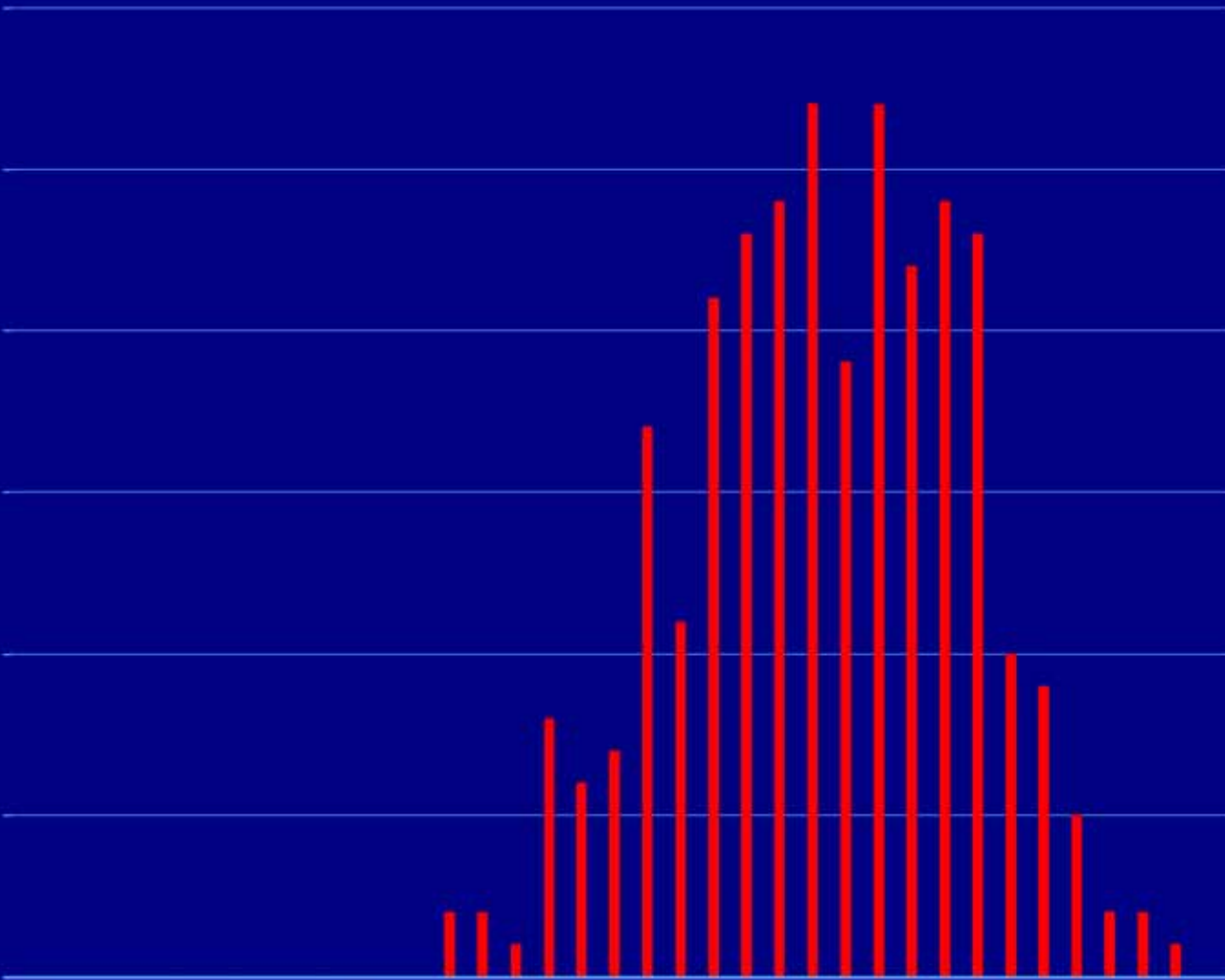
5

0

H. pylori
present



0 5 10 15 20 25 30 35
Grades of gastritis



HELICOBACTER AND GASTRITIS

Patients

30

25

20

15

10

5

0

0

5

10

15

20

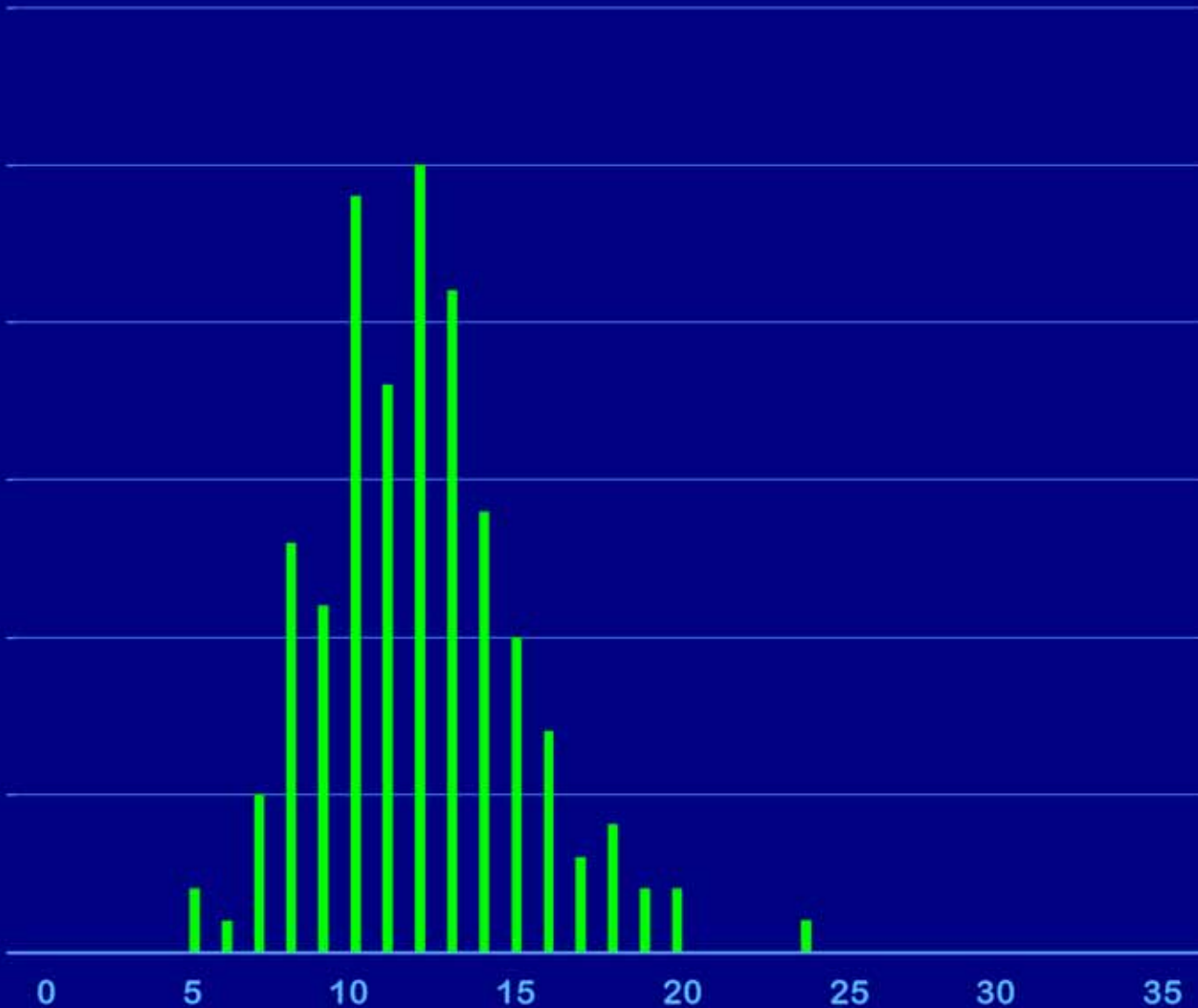
25

30

35

Grades of gastritis

H. pylori
eradicated



HELICOBACTER AND GASTRITIS

Patients

30

25

20

15

10

5

0

H. pylori
present

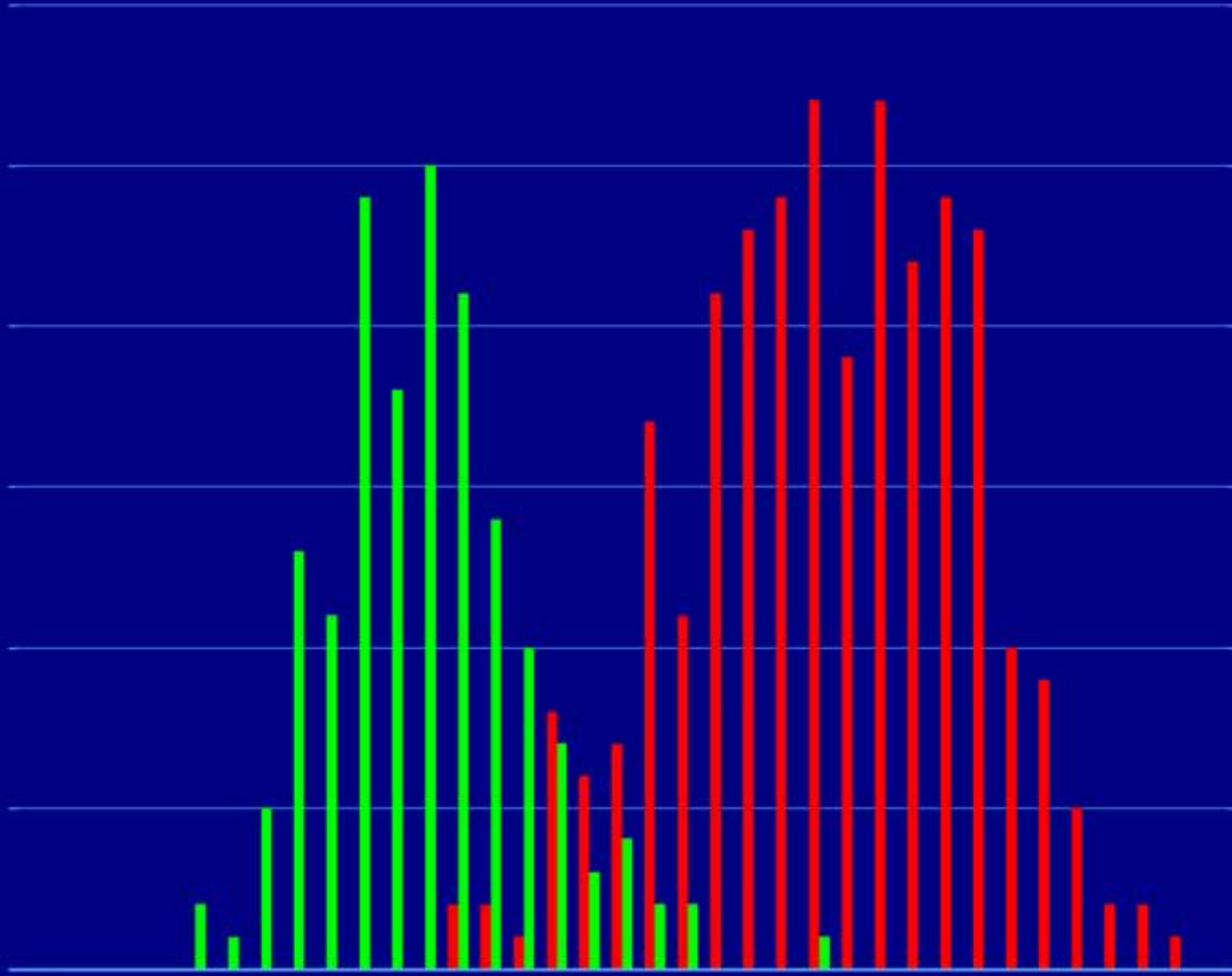


H. pylori
eradicated



0 5 10 15 20 25 30 35

Grades of gastritis



DUODENAL ULCER

- Distal gastric

- Gastric mucosa

- Extends into duodenal cap

- Forms proximal border of duodenal ulcers

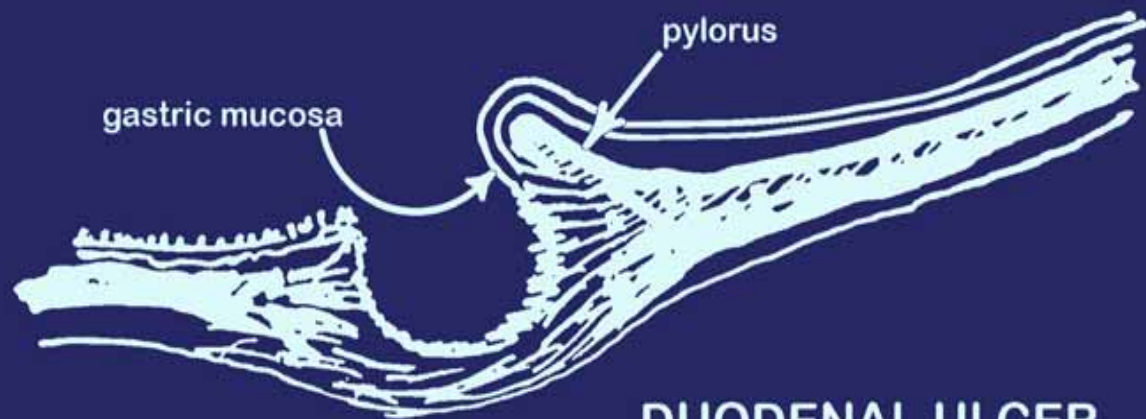
- Other borders are duodenal

- Usually inflamed and scarred

- May show gastric metaplasia with *H pylori*

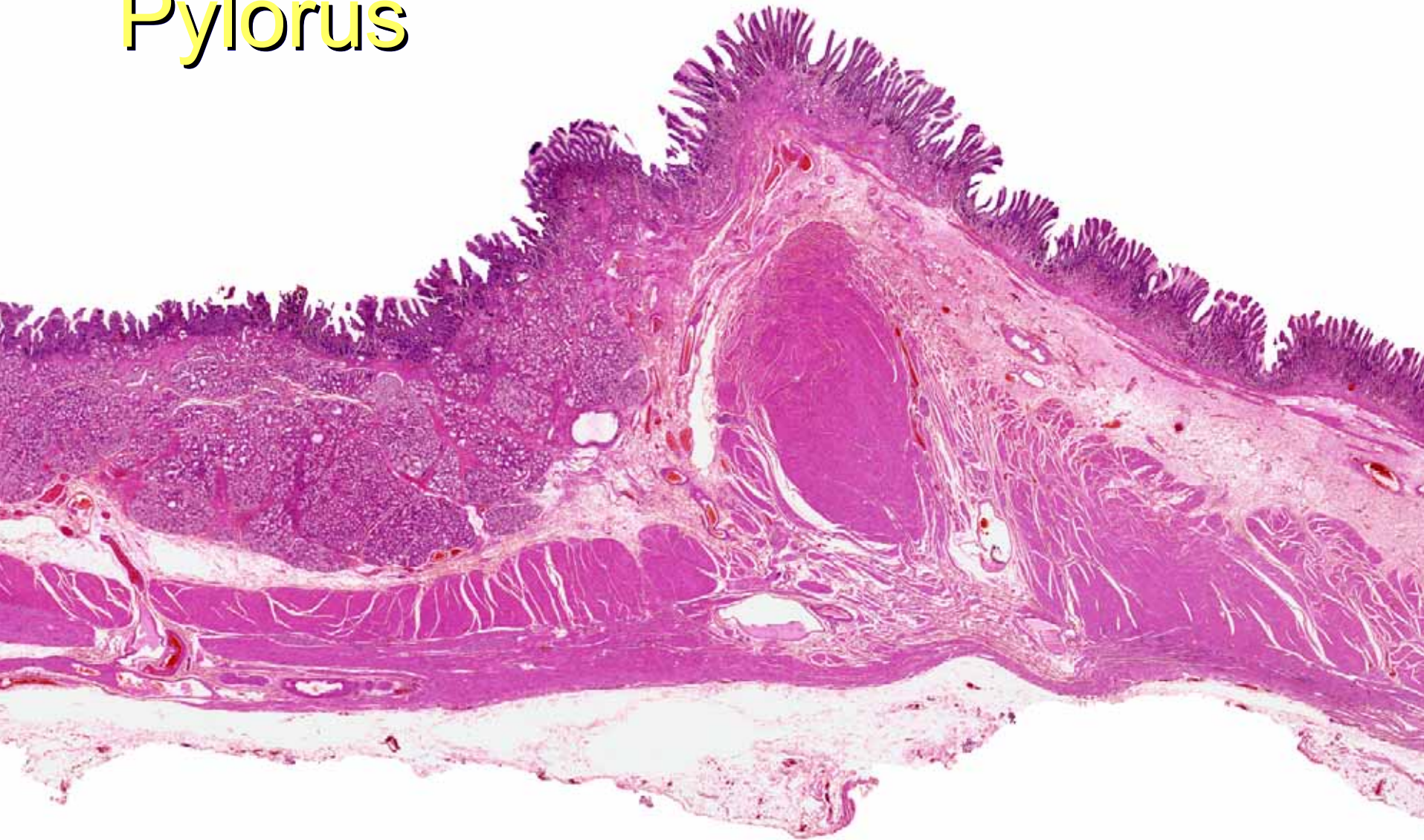


NORMAL PYLORUS

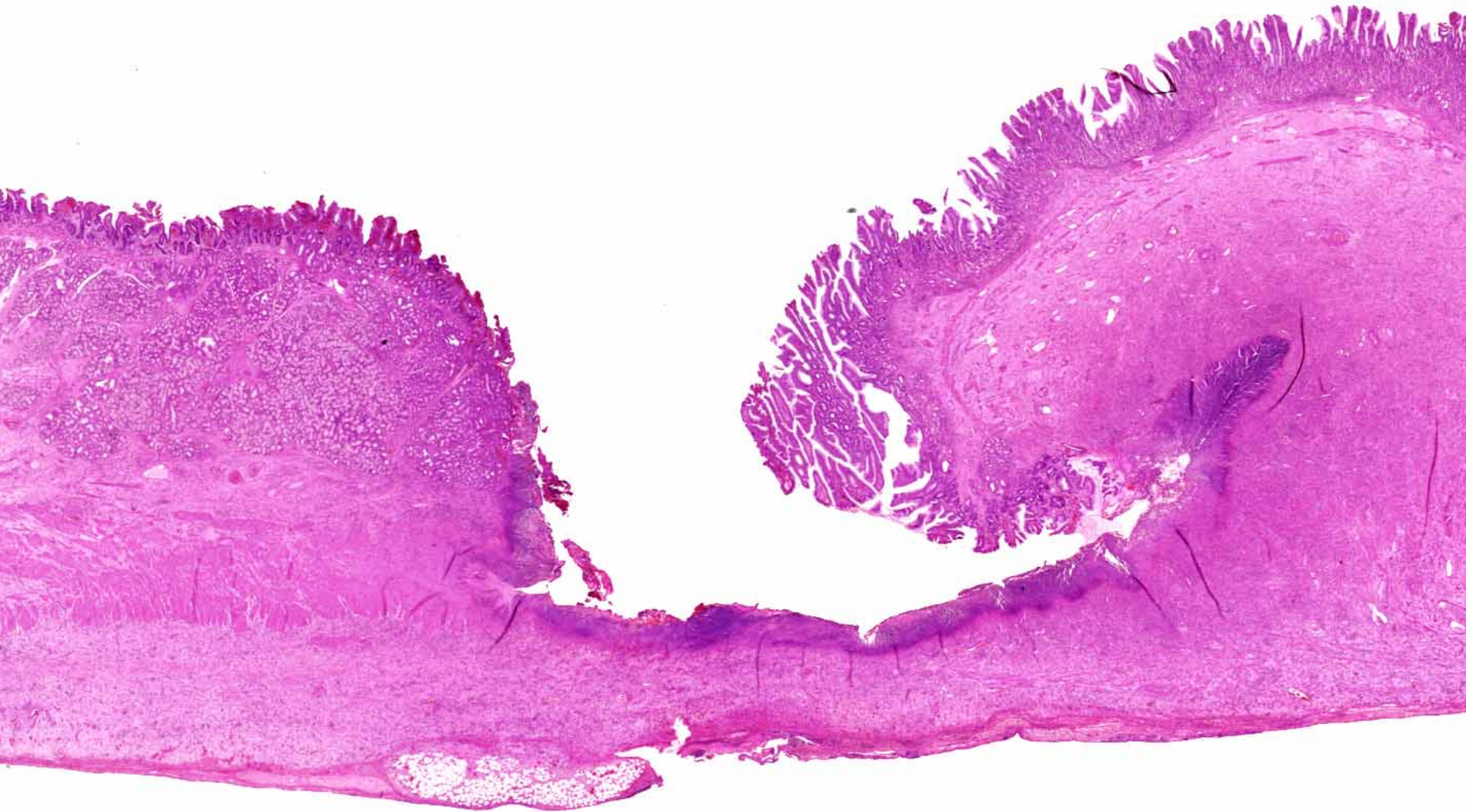


DUODENAL ULCER

Pylorus



Duodenal ulcer



HELICOBACTER NOW

- The **importance of *H pylori* is accepted** worldwide
- **Duodenal ulcer**, required treatment
- **Gastritis**, recognised aetiology, not the importance
- WHO listing as a **carcinogen**
- Related to gastric carcinoma and MALT **lymphoma**

- Possibly associated with **coronary artery disease**
- Big money: drug companies and research
- Governments considering cost of total eradication

CONCLUSION

- Gastric bacteria: known for 100 years and ignored
- Seen by me and linked to gastritis

WITH DR BARRY MARSHALL

- we cultured *H pylori*
- linked it to duodenal ulcer
- fulfilled Koch's postulates for clinical disease and
- eradication cures gastritis and peptic ulcer disease